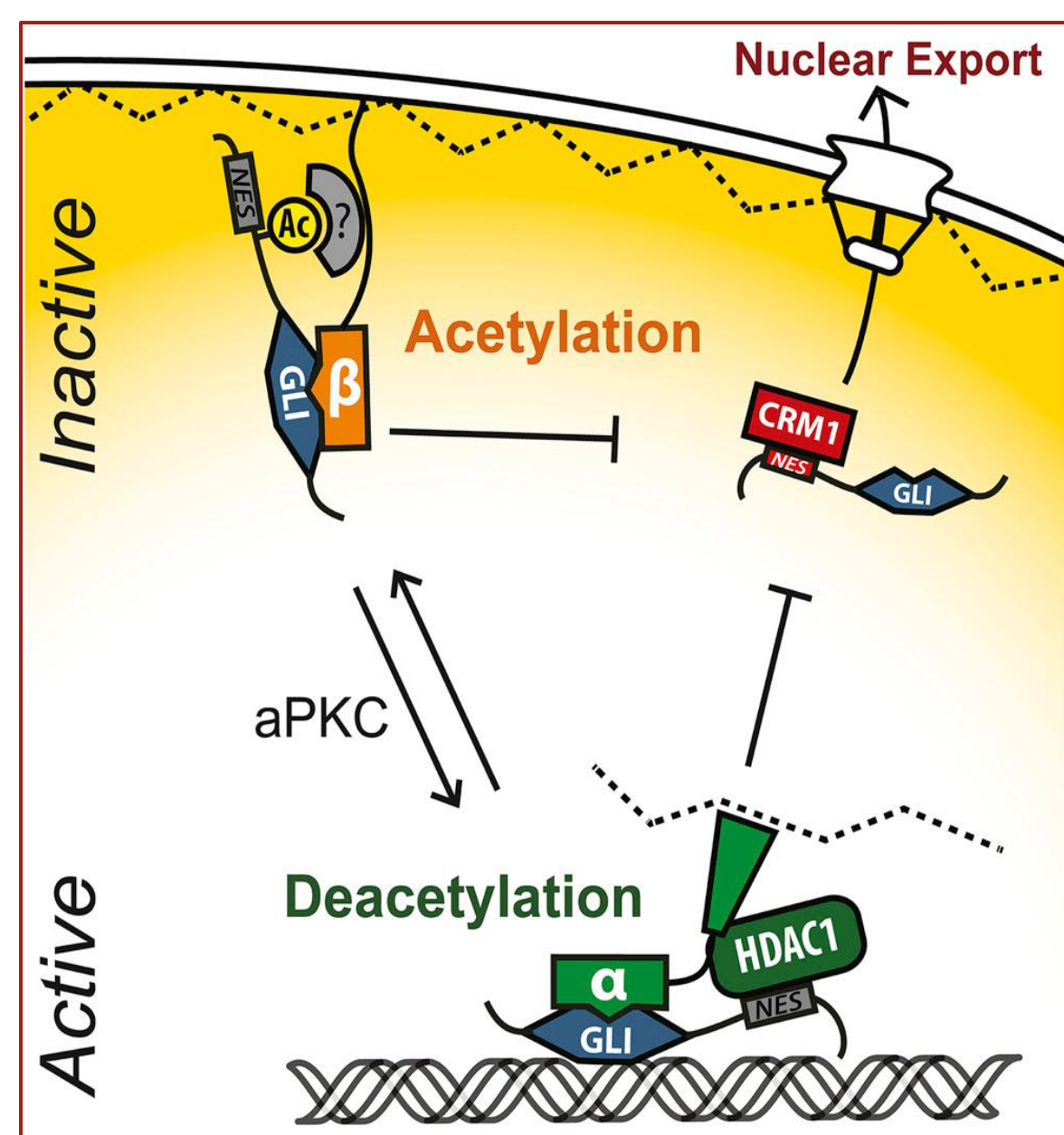


An Open-label Phase 2 Clinical Trial of Topical Remetinostat for Basal Cell Carcinoma

Nicole Urman B.S., Shaundra Eichstadt M.D., Hanh Do B.S., Amar Mirza B.S., Anthony E. Oro M.D. Ph.D., Sumaira Aasi M.D., and Kavita Y. Sarin M.D. Ph.D.
Program in Epithelial Biology, Stanford Department of Dermatology

Introduction

There is a great need for non-surgical therapies for patients with frequent basal cell cancers (BCCs) as the repeated surgeries can lead to severe morbidity and functional impairment. We conducted a systematic computational drug repositioning screen which identified histone deacetylase (HDAC) inhibitors as a potential therapy for BCC. We showed that HDAC inhibitors can suppress Hedgehog signaling and growth of BCC cells and murine BCC allografts, though optimal therapeutic effect was limited by systemic toxicity. Here, we report interim results of an open-label clinical trial of the topical HDAC inhibitor, retinostat, as a neoadjuvant treatment for BCC. Retinostat is designed to be metabolically labile so that topical application produces effective local HDAC inhibition in tumors while minimizing systemic HDAC inhibition and toxicity.



Mirza, A. et al, *Cell* 2019

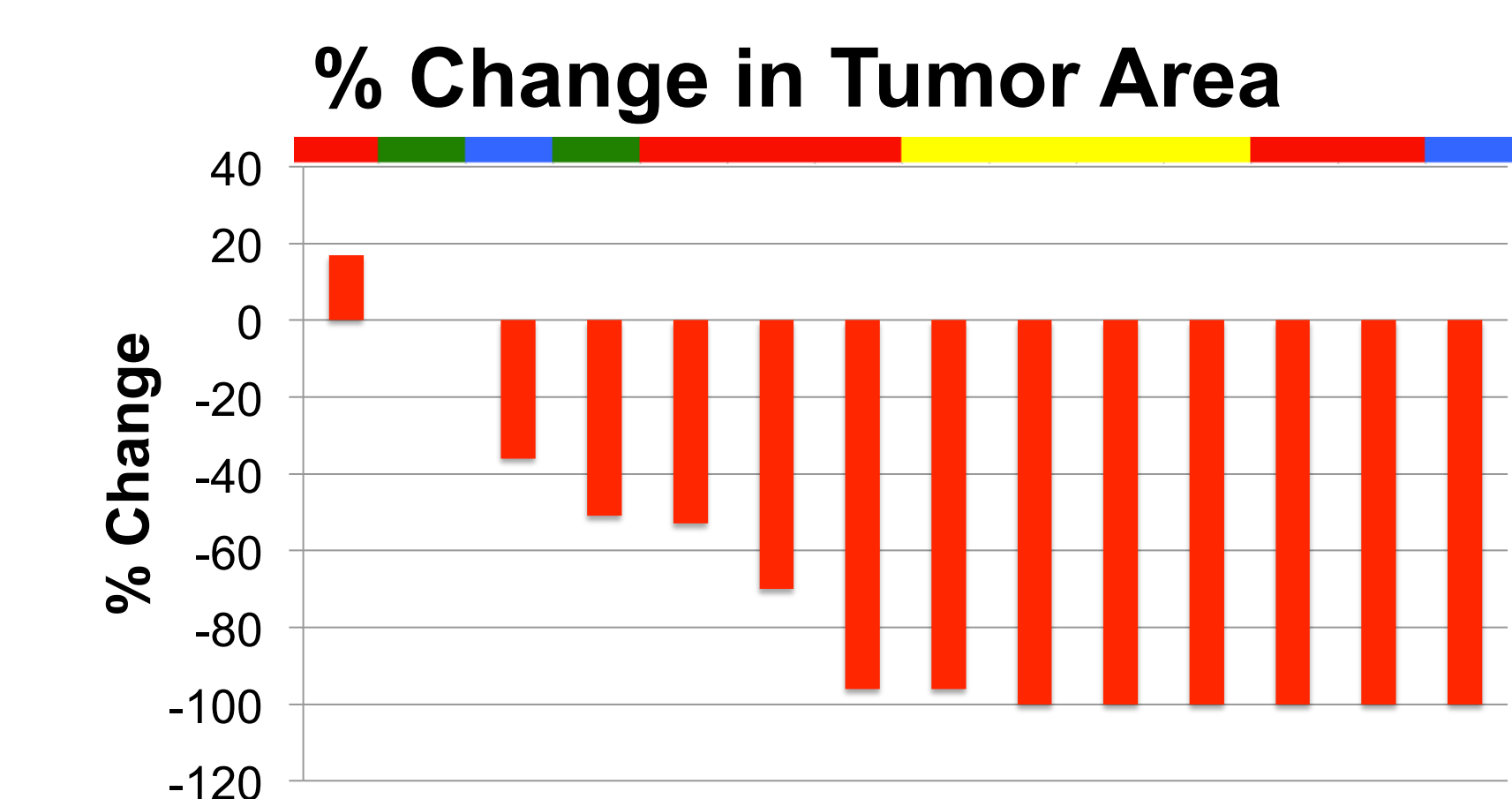
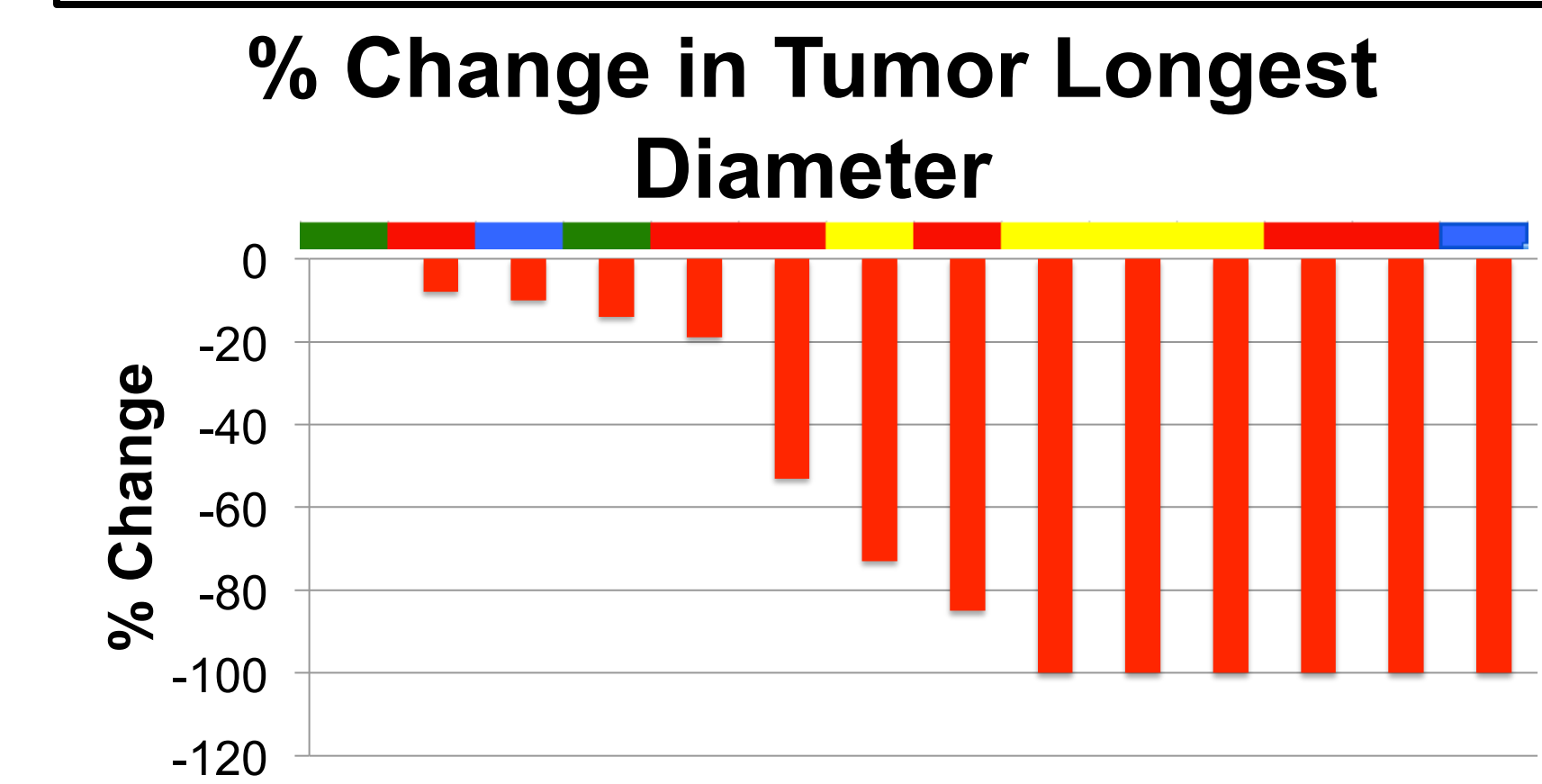

Trial Design

- Enrolled subjects had at least 1 BCC of any subtype between 5 and 25mm in size.
- Participants applied retinostat gel 1% 3 times/day under bandage occlusion to BCC(s) for 6 weeks prior to undergoing surgical excision.
- The primary outcome was overall response rate (ORR) measured by at least a 30 percent decrease in BCC greatest diameter. Secondary objectives include suppression of Gli1 mRNA expression and the safety and tolerability of retinostat.

Enrollment and Interim Results

- Current enrollment: 14 participants (30 tumors). Goal enrollment: 30 tumors.
- Anticipated timeline: final patient completed by December 2019
- 3 participants (15 tumors) removed for compliance < 70%. 1 participant currently in trial.

Results:

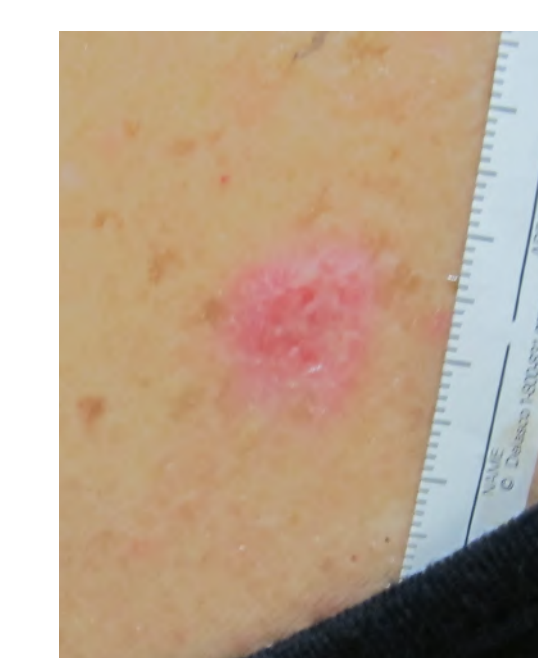
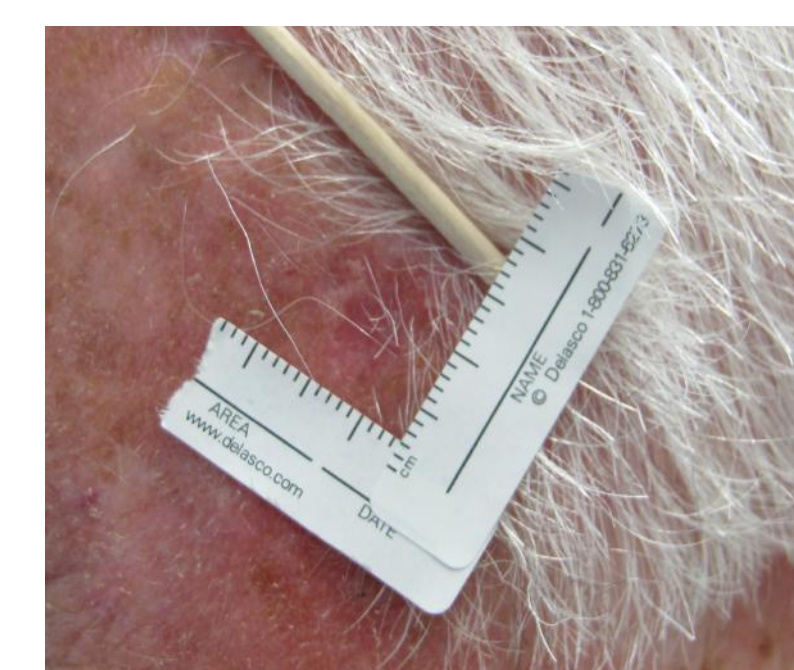
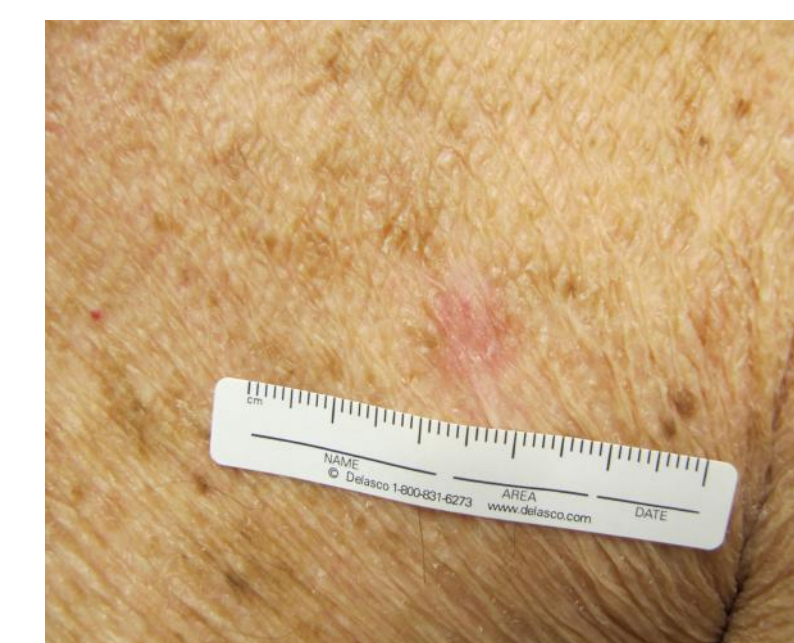
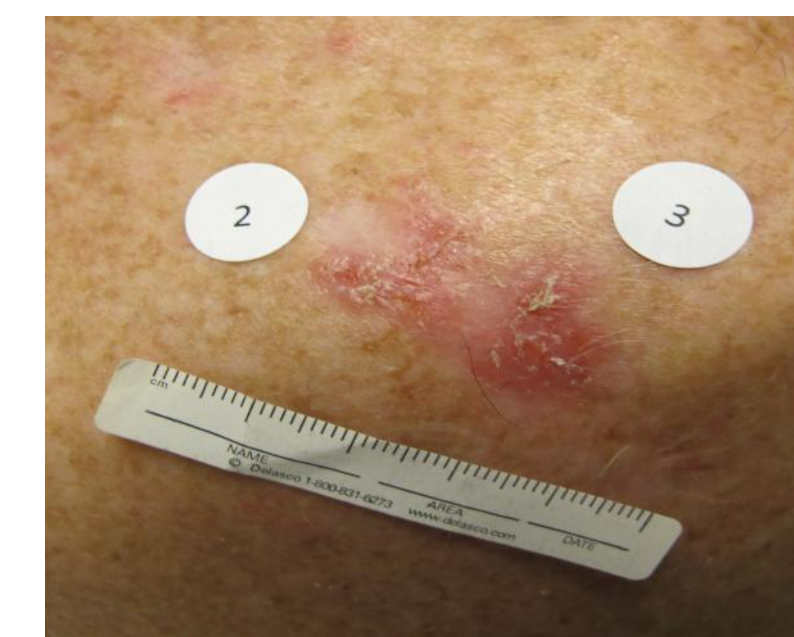Adverse Events:

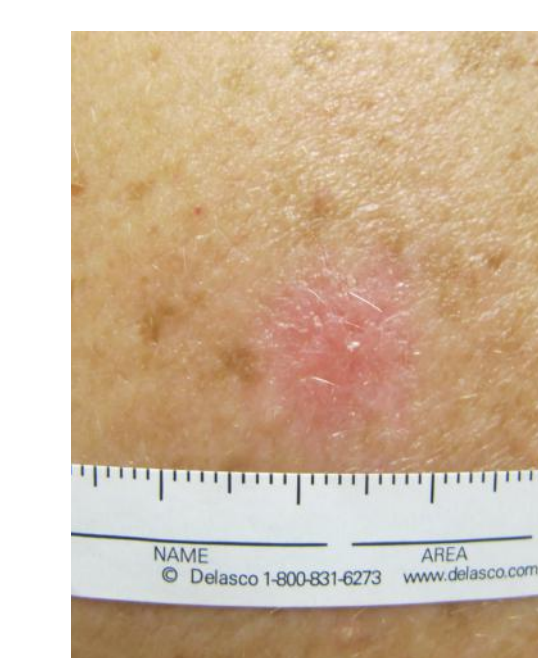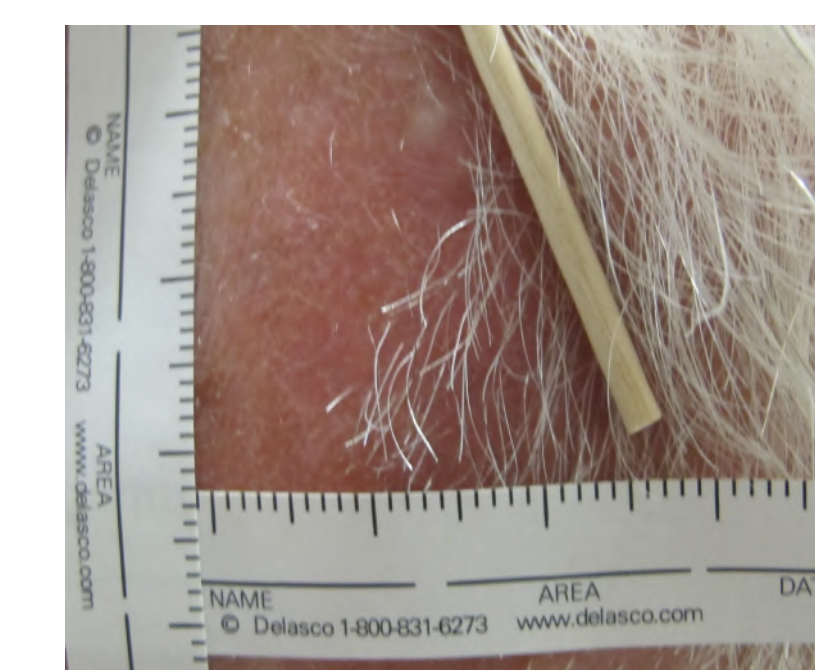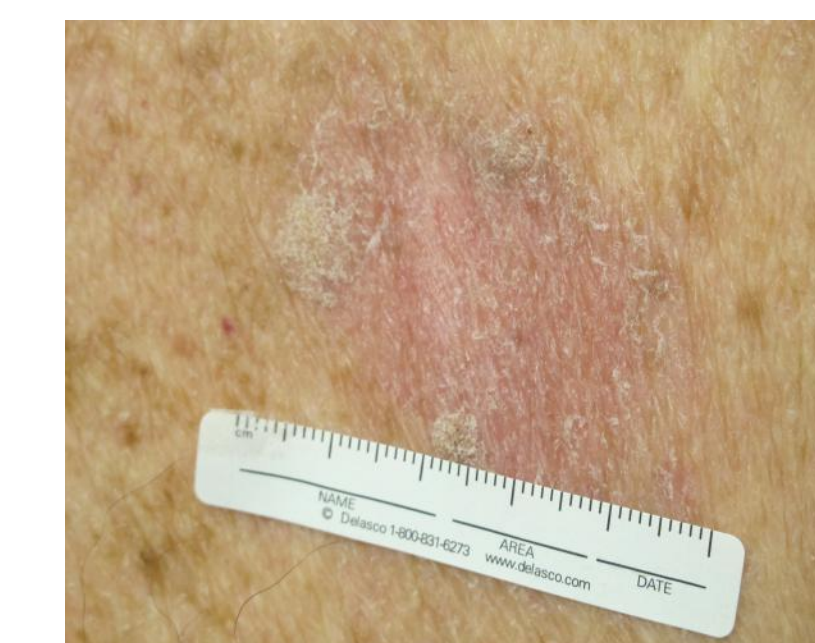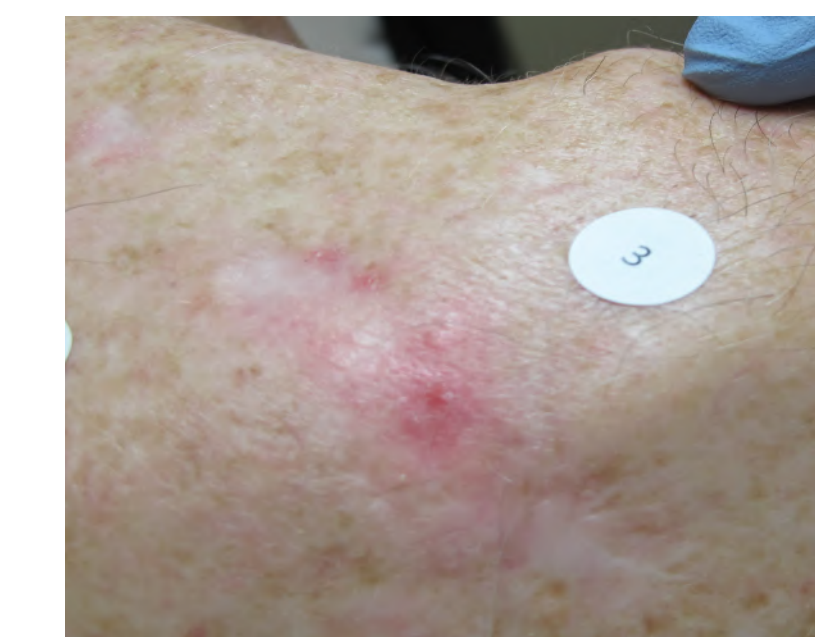- Patients develop grade 1-2 eczematous reaction +/- pain at application sites
- Anecdotally associated with use of occlusive dressings, tumor shrinkage/clearance
- Can obscure edges of tumor
- 2 of 14 subjects had their study drug temporarily discontinued (for 1-3 days) due to AEs
- Improves within ~ 2-4 weeks of discontinuing medication

Adverse Event (AE)	Severity of AE	Number of subjects reporting AE (% patients, n=14)
Eczema	1-2	10 (71%)
Pain	1-2	5 (36%)

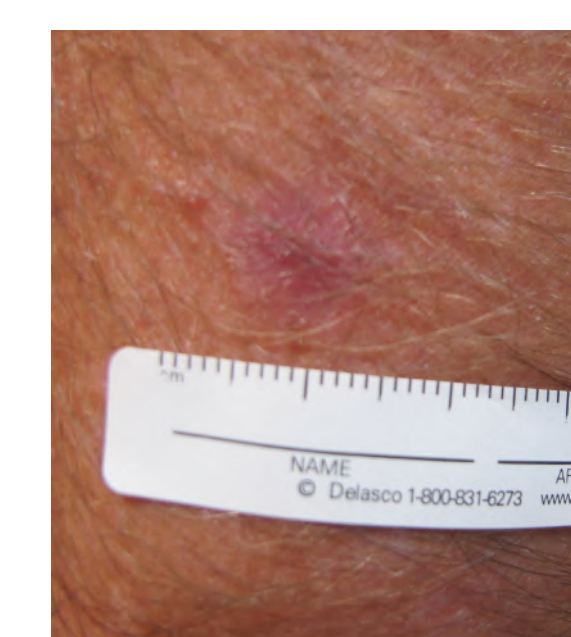
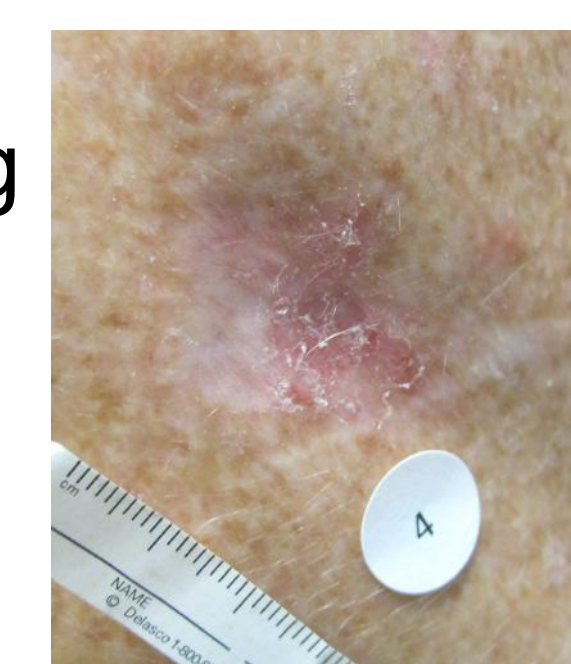
Week 0:



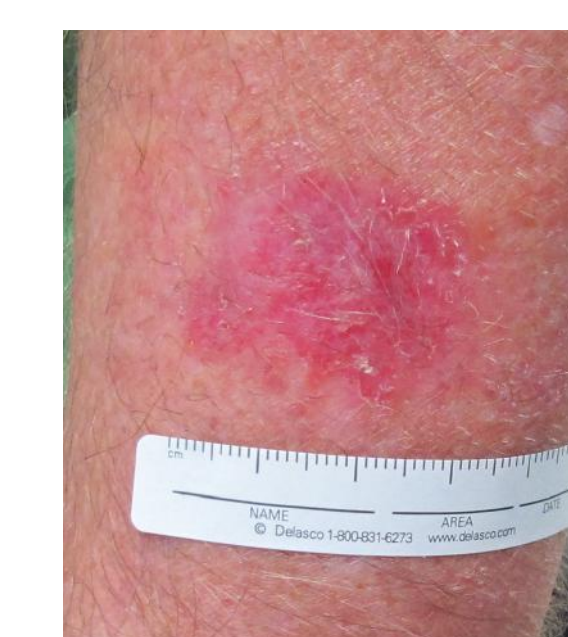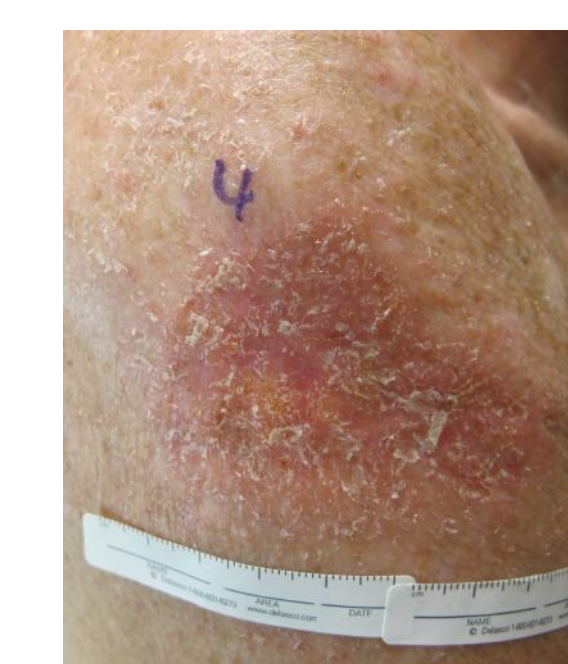Week 8:



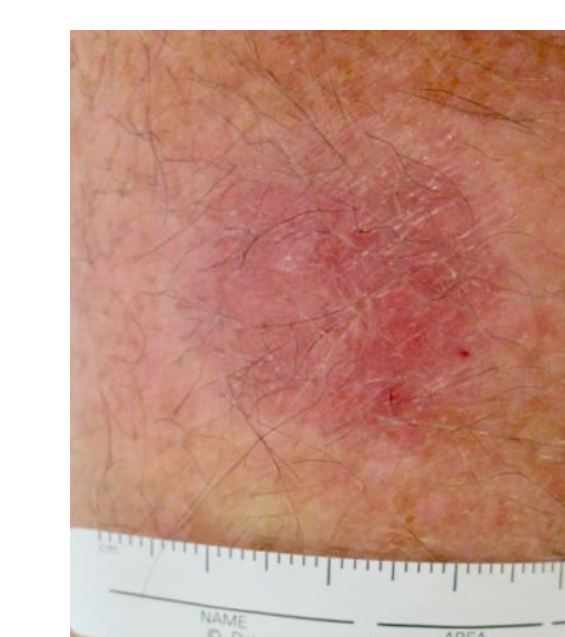
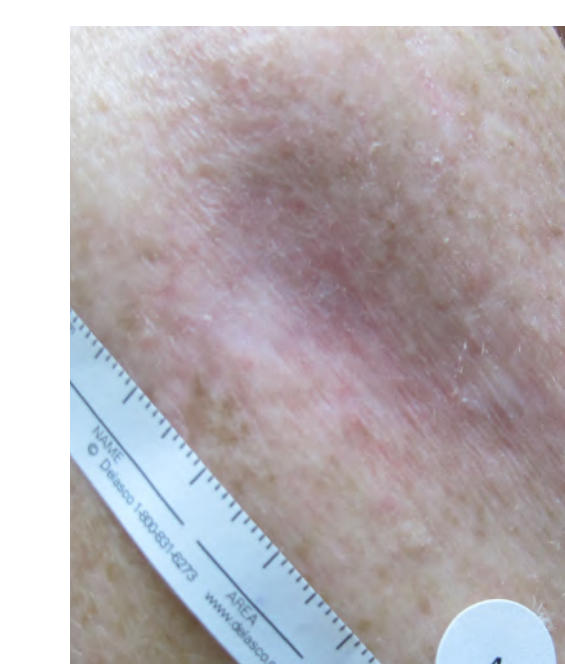
Week 0



Week 4 AEs

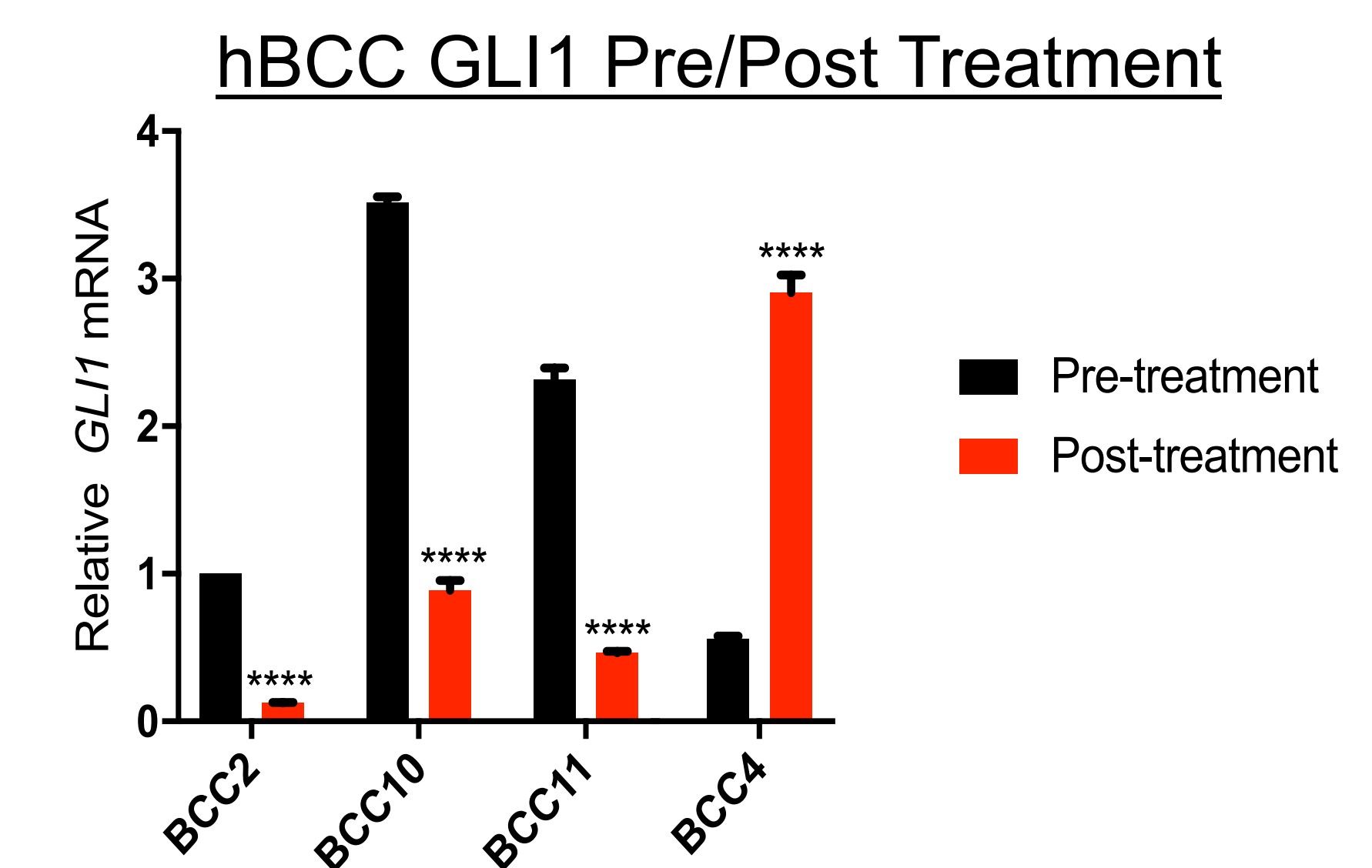


Week 8 AEs



Results - qPCR

- Participants could choose to opt in to having pre- and post-treatment biopsies taken and analyzed via qPCR for *PTCH* and *GLI1* mRNA.
- GLI1* mRNA level changes, post-treatment: 8-fold, 4-fold, 5-fold decreases, 5-fold increase



Conclusions

- The ORR, at least a 30% decrease in longest diameter, was 64% (9/14).
- The average decrease in tumor area is 70% (n=14), while the average decrease in longest diameter is 62% (n=14). 43% (6/14) of tumors were fully cleared
- Grade 2 eczematous local site reactions occurred in 71% (10/14) tumors treated with topical retinostat.
- No systemic toxicities have been observed.
- Barriers to effective treatment include refrigeration of retinostat gel and 3x/day application with occlusion for 6 weeks.
- Initial results suggest that retinostat gel offers a potentially effective, non-surgical intervention for treatment of localized BCCs.

References

- Mirza, A. et al, *Cell*, 2019
- Mirza, A. et al, *JCI Insight*, 2017

Acknowledgments: Thank you to Medivir, the American Skin Association, Albert M. Kligman Travel Fellowship, and Stanford Medical Scholars Research Program for funding this project and presentation

Contact Information: Nicole Urman, nurman@stanford.edu, Department of Dermatology, Stanford, CA 94305